Proximal One-Portal Blind Over Guide

A new technic for Carpal Tunnel RELEASE

by

Dr. Dinis Carmo, MD

www.ortopedia-diniscarmo.com

Guided, controled

section of the carpal tunnel ligament

without previous

dilation of the content of the carpal tunnel and

final endoscopic check-up

Patient, day one after surgery: The surgical (only) incision in less than 1cm

Released carpal Tunnel Ligament

the 2 divided parts of the ligament are displayed

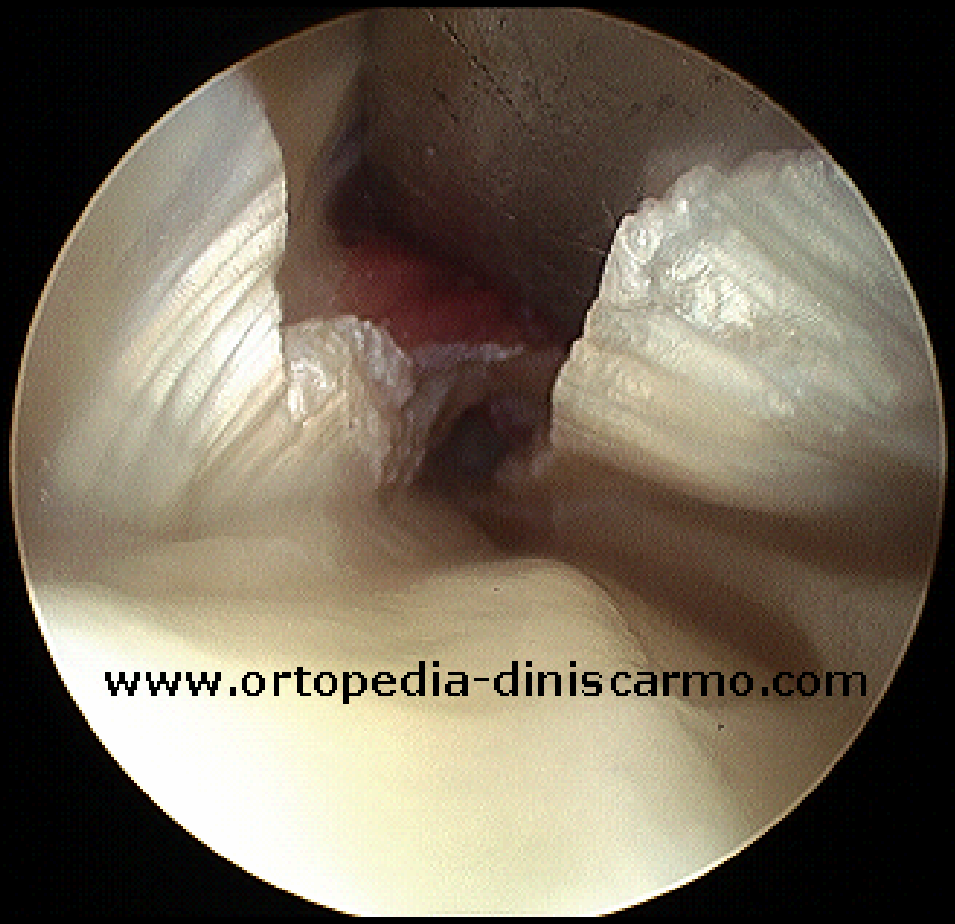

our technique is:

- *simple*
- *fast*
- *SAFE*
- *easily reproducible*
- *economical*
- *use of the endoscope is optional* (mainly for documentation)

What is new?

A Guide system

and

Modified blades

The Guide system

allows for the SAFE division of the carpal tunnel ligament

- **Under control**
- **Without the need of previous dilation of the content of the carpal tunnel**
- **Without the need of an endoscope**

Other important surgery features:

- We have been using this technique since 2005.
- So far more than 100 patients have been operated with this technique without any reports of significant complications
- Minimally invasive surgery: a 1cm proximal portal only incision
- Minimally painful surgery: most patients do not need post-op. analgesia
- Average surgery time: 15m
- Documented surgery: photo and /or video

warning:

- for protection of author's rights the guide system used for the surgery is currently NOT RELEASED.
- Only the clinical results and underlying philosophy are displayed

Carpal Tunnel Syndrome : what is the cause of the problem?

The median nerve, one of the most important hand nerves, passes UNDER the carpal tunnel ligament, therefore, it may be compressed under it.

www.ortopedia-diniscarmo.com

Median nerve: course in the upper extremity

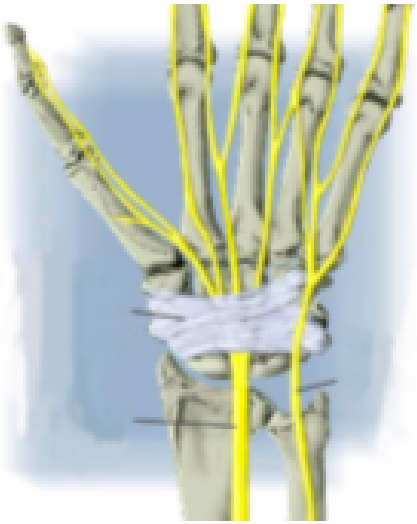

Median nerve at the wrist: the nerve travels UNDER the Carpal Tunnel Ligament.

fingers normally enervated by the median nerve

the Solution:

surgical release of the carpal tunnel ligament

www.ortopedia-diniscarmo.com

A BIT OF HISTORY

about the surgical technique(s)

Surgical techniques available for the release of the CTL

- classic "open" surgery
- "mini-open" techniques
- endoscopic techniques
- "blind" techniques

Common used incisions for carpal tunnel release

2 of the most common incisions used for "open" CTR

some of the most common incisions used in mini-open and endoscopic techniques. In many, two combined incisions ("double portal" techniques) are used.



www.ortopedia-diniscarmo.com

A BIT OF HISTORY

what is the problem with

-1 -

classic "open" surgery?

Classic "open" Surgery

Open surgery is straight forward, simple, easy, accessible to less differentiated surgeons and inexpensive. Results are generally good.

The problem is: the possibility of persistent residual pain at the level of the incision (local or pillar pain)

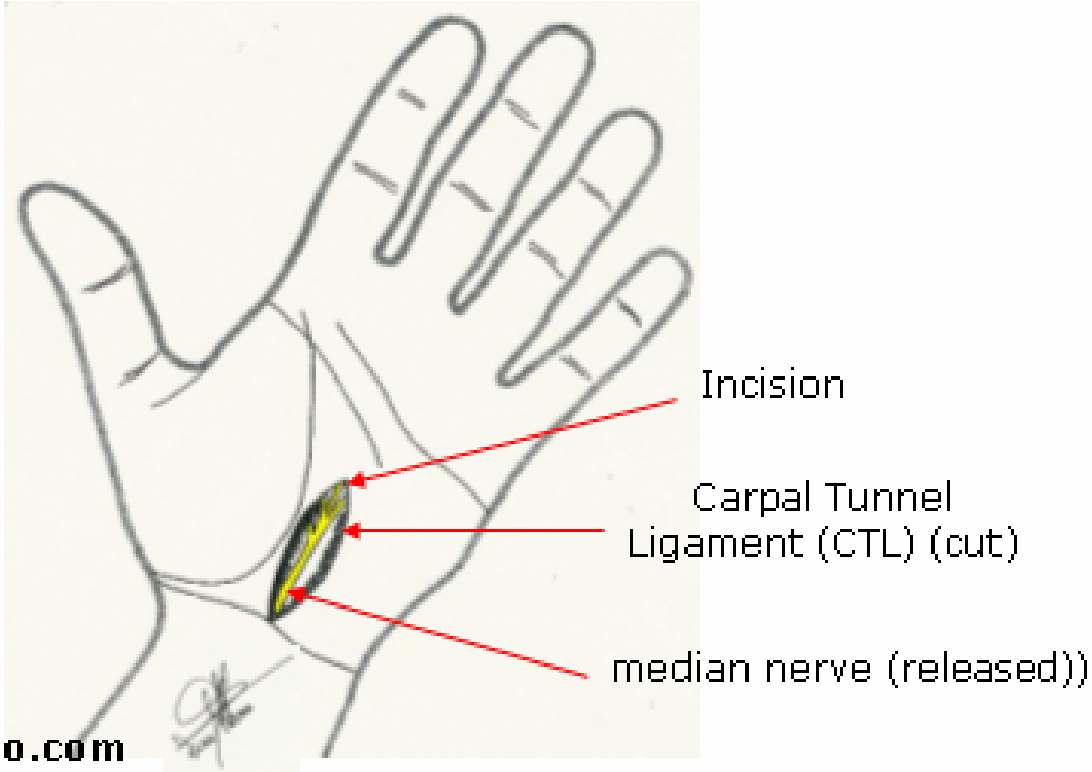

A BIT OF HISTORY

what is the problem with

-2-

"mini-open" surgery?

"Mini-Open" Techniques

One or two smaller incision(s) is(are) performed

The aim is to diminish local or pillar pain

The Problems are:

- the concept of "mini" is subjective. Some techniques use 2 incisions.
- most of these techniques are, at least, partially "blind", with deep incisions extended blindly through minor superficial (skin) incisions.
- they can be potentially traumatic. If too vigorous retraction is applied the problem of local or pillar pain can persist or even be aggravated.
- **the potential for post-op. complications increases.**

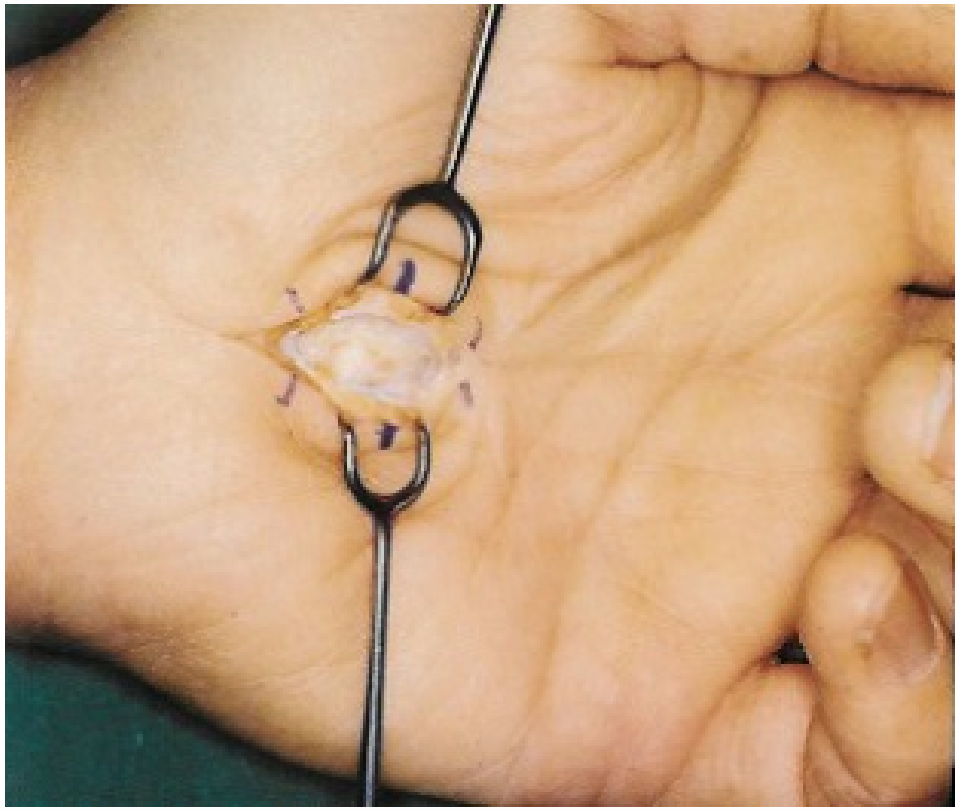

www.ortopedia-diniscarmo.com

A BIT OF HISTORY

what is the problem with

-3 -

"blind" surgery?

Blind Surgery

"Blind" surgery is actually a "mini-open" surgery, in which the small(s) incision(s) practiced for endoscopic surgery is(are) used and the operation carried forward "blindly" guided by the "experience" or "feeling" of the surgeon as to how and when the CTL is released. The idea is to take advantage of the small incisions practiced without the cumbersome use of the endoscope. A few surgeons use it.

The main problem is the lack of control and documentation about the performed release. It is prone to litigation and in countries where medical malpractice is common, like the USA, it is certainly a surgeon's major hazard.

To the best of our knowledge there are no scientific papers published with the results of this particular type of technique.

A BIT OF HISTORY

what is the problem with

- 4 -

endoscopic surgery?

A BIT OF HISTORY

a) why did endoscopic techniques became popular in the first place?

Endoscopic Techniques

The development of endoscopic techniques for CTR was almost inevitable, following the success of these techniques in other areas, mainly surgery of the knee.

Several techniques and its variants were published and became more or less widespread with different degrees of acceptance and popularity.

Once again the main goal was to decrease local/pillar pain and speed up recovery.

*As a result, **several sets** manufactured and commercialized by **several companies** for the release of the carpal tunnel became available in the market.*

A BIT OF HISTORY

b) why are endoscopic techniques dramatically fading from favor ?

what are the problems with Endoscopic Techniques?

1

Many hand surgeons have abandoned endoscopic techniques because they feel that the technique is:

- expensive
- demanding
- potentially dangerous
- the risk of causing a serious intra-operative lesion that may be (at least partially) irreversible does not justify the benefit of a smaller scar and discomfort.

what are the problems with Endoscopic Techniques?

2

as far as we are concern, it is our belief that two major problems of endoscopic carpal tunnel release are related to:

- subspecialization of the hand surgeons
- the need for previous dilation of the content of the carpal tunnel prior to cutting the Carpal Tunnel Ligament (CTL)

what are the problems with Endoscopic Techniques?

3

- ***subspecialization of the hand surgeons***

  - it is our feeling that in many cases, specially in the USA, subspecialization leads to the fact that surgeons that are proficient in endoscopic techniques do not routinely perform hand surgery and many hand surgeons do not have enough endoscopic training

  - **SOLUTION: use of a technique that is not endoscopic dependent**

what are the problems with Endoscopic Techniques?

4

- ***the need for previous dilation of the content of the carpal tunnel prior to cutting the Carpal Tunnel Ligament***

do to the resulting compression of the soft structures during dilation, the contents of the canal, namely the median nerve itself and/or the tendons can slide inside the cannula/the knife track and be exposed to injury

- Solution: use of a technique that does not require dilation of the carpal tunnel

Why do we feel it is so important to release the CTL WITHOUT previous dilation of the carpal tunnel canal?

1) The carpal tunnel is NOT expansible. As previously stated, that is the cause of the problem in the first place

2) Most if not all endoscopic techniques require making room for insertion of a cannula through which the endoscope and the cutting knife are to be introduced. This can only be achieved at the cost of the compression of the soft structures therein. Besides, the cannula has a diameter that may very well be 30% or more of the tunnel. This potentially endangers the contents of the tunnel as just mentioned before

Example of a previously commercially available kit consisting of 2 dilation rods and a cannula with removable obturator. The production of this particular kit was later discontinued by the manufacturer

what are the problems with Endoscopic Techniques?

5

Other Technical Problems:

- many are **two incisions techniques**

Overall, the size of the two incisions together is not much smaller than the single incision used in classic, "conservative" surgery. In some, one of those incisions is over the pillar area of the hand.

- **technical difficulties** in
  - adequate visualization throughout the procedure
  - adequate exposure of the inner side of the carpal ligament
  - orientation
  - cutting safely through the entire length of the ligament

- **economical factors** (expensive kits)

Endoscopic Techniques - **where do we stand today?**

- do to technical dificultties and complications all-endoscopic carpal tunnel release has dramatically faded from favor in the USA. The same is probably true worldwide

- a survey from the most recent American Society for Surgery of the Hand annual congress showed that of the membership,

  . 78% do a mini-open CTR,

  . (ONLY) 20% do all-endoscopic CTR,

  . and 2% do "other".

as stated, our technique is:

- *mini- invasive*
- *guided, simple, fast,*
- *easily reproducible*
- ***SAFE***

some other clinical examples

Our technique:

the usual incision is a proximal unique transverse incision of one or less centimeter, placed over the distal wrist crease. This minimal incision is closed with 2 or 3 absorvable stitches.

To the best of our knowledge, there is no smaller incision described worldwide for this type of operation

skin incision

Same patient

6 weeks post-op.

4 months post-op.

to which hand was the patient operated to?

both, simultaneously

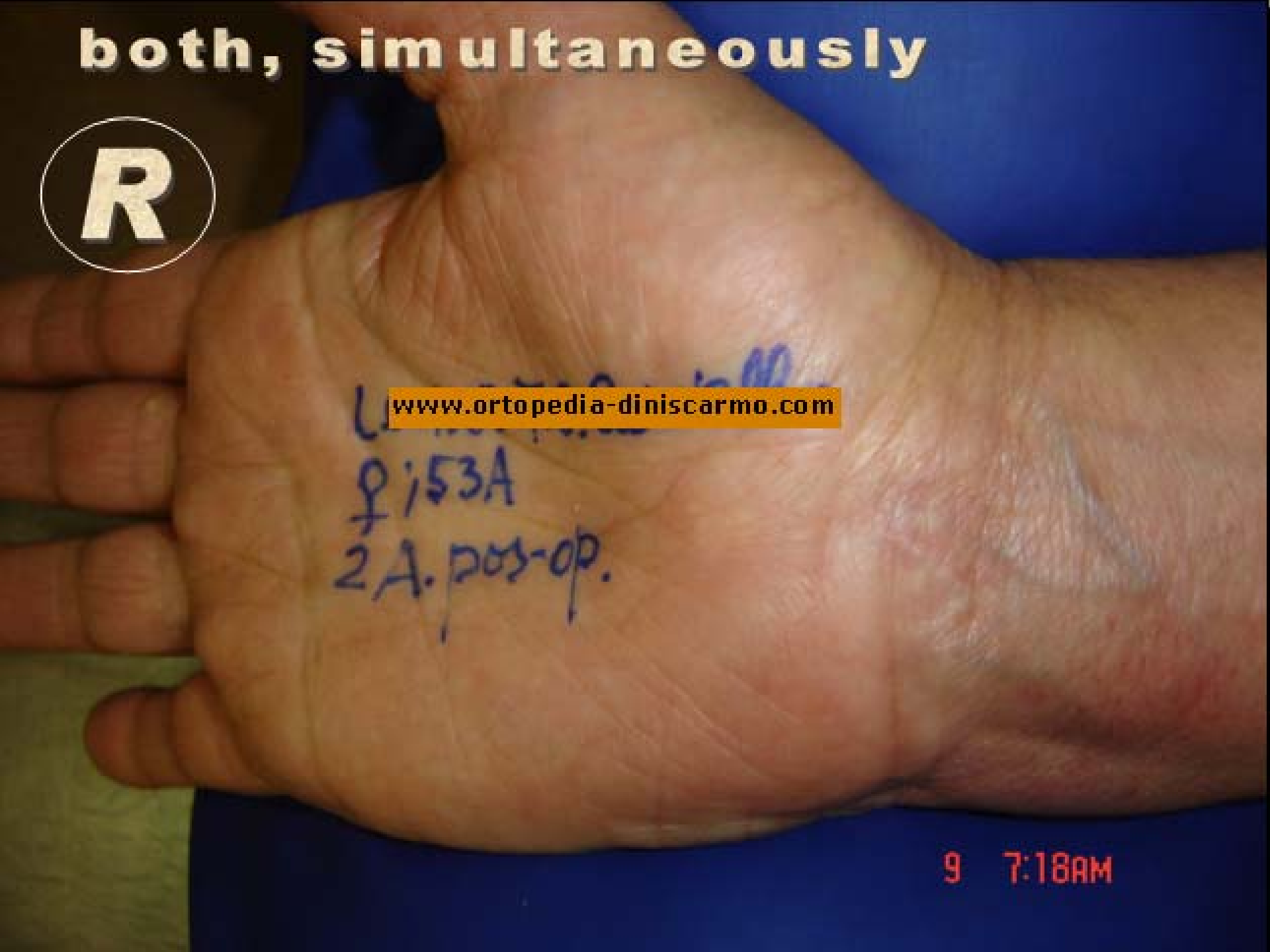

in June, 2005
L
www.ortopedia-diniscarmo.com

1 month post-op.
9 months post-op.
www.ortopedia-diniscarmo.com

Intra-op. photo demonstrating the division of the CTL. - (1)

Hand orientation:
palm up. Surgical incision represented in red

Legend:

1) surgical instrument
2) same
3) radial ½ of the cut carpal tunnel ligament (CTL)
4) cubital ½ of the cut carpal tunnel ligament (CTL)
5) subcutaneous fat (palmar)

Intra-op. photo demonstrating the division of the CTL. - (2)

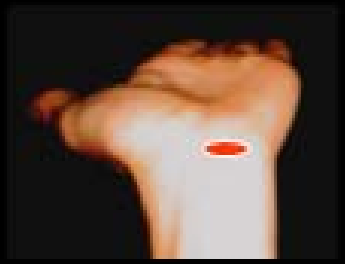

Hand orientation:
palm up. Surgical incision represented in red

Legend:

1) surgical instrument
2) radial ½ of the cut carpal tunnel ligament (CTL)
3) cubital ½ of the cut carpal tunnel ligament (CTL)
4) subcutaneous fat (palmar)
5) underlying contents of the canal: synovial lining covering nerve and tendons (not disturbed)

Intra-op. photo demonstrating the division of the CTL. - (3)

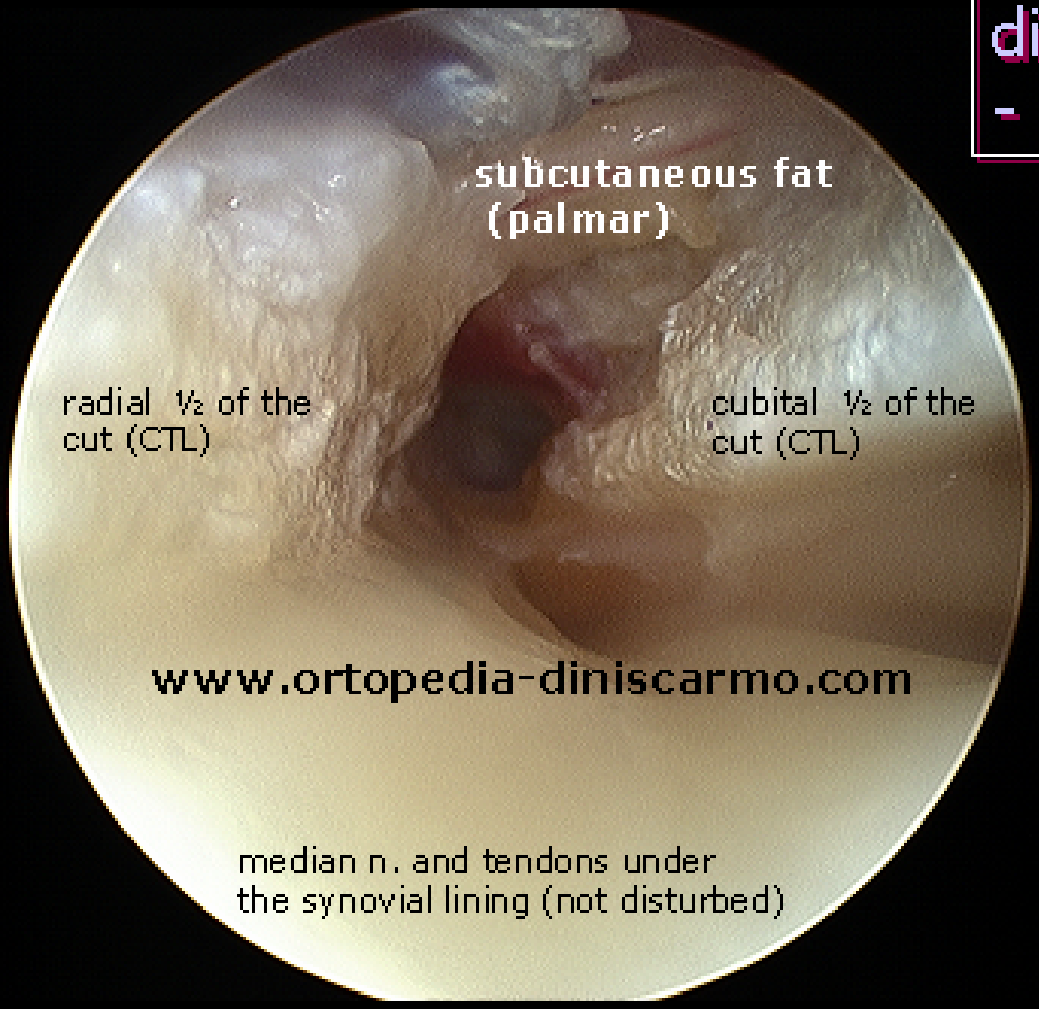

Vídeo of the released carpal tunnel ligament.

www.ortopedia-diniscarmo.com

picture from the previous film

subcutaneous fat
(palmar)

radial ½ of the
cut (CTL)

cubital ½ of the
cut (CTL)

www.ortopedia-diniscarmo.com

median n. and tendons under
the synovial lining
(not disturbed)

resume of the main diferences between our technique and each of the existing ones

concerning "classic", open, Surgery

www.ortopedia-diniscarmo.com

- smaller incision/ smaller scar
- no cuts over the pillar area of the hand
- faster
- much more comfortable for the patient

concerning "Mini-open" Surgeries

www.ortopedia-diniscarmo.com

- smaller incision
- one proximal incision only
- no cuts over the pillar area of the hand
- CTL cut guided, under control. Many of the so called "mini-open" techniques are, at least partially blinded techniques
- documented

concerning endoscopic techniques

www.ortopedia-diniscarmo.com

- no previous dilation of the carpal tunnel
- Simple
- Safe
- Fast
- *Economical*
- *endoscope use optional (mainly for documentation)*

concerning "blind" techniques

www.ortopedia-diniscarmo.com

"blind surgery is for blind surgeons, blind about their results"

- the section of the CTL is done under control
- the results of the surgery is documented

in Conclusion

what was our contribution for the advancement of the carpal tunnel release surgery?

in Conclusion

- the devellopment of a guide system and modified blades that allows for the:

  - SAFE, controled division of the carpal tunnel ligament

  - without the need for previous dilation of the contents of the carpal tunnel

  - without the need of the endoscope (except for documentation)

in Conclusion III

Our technique is :

- guided
- documented
- ***SAFE:*** no report of any significant complications in more than ***100*** cases

contacts

www.ortopedia-diniscarmo.com

phone: (351) 22 600 13 13

fax: (351) 22 600 40 01

e-mail (overseas - English only):

geral@ortopedia-diniscarmo.com

mail address: Av. Boavista, 117, sala 306
4050-115
Porto - Portugal